Basic Principles for the Reconstruction of the Chest Wall

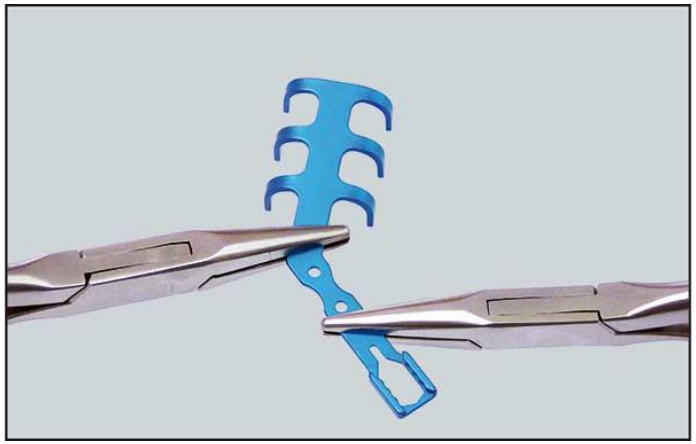

Pierre-Emmanuel Falcoz

Dept. of Thoracic Surgery – Strasbourg University Hospital

Les Hôpitaux Universitaires de STRASBOURG

UNIVERSITÉ DE STRASBOURG

Chest wall reconstruction need

- Primary chest wall tumor resection
- Secondary chest wall tumor resection
- Infections of chest wall elements
- Post radiation necrosis

Classification

1. **Primary neoplasm of chest wall**

1. **Metastatic neoplasms to chest wall**
   sarcoma
   carcinoma

1. **Adjacent neoplasms with local invasion**
   lung
   breast
   pleura

1. **Non-neoplastic diseases**
   cysts
   inflammatory lesions
   infections
   Post radiation necrosis

INCIDENCE

- Primary chest wall tumors are uncommon
- 50-80 % are malignant
- Soft tissues are major sources of chest wall tumors
- The most common primary MALIGNANT chest wall tumors are malignant fibrous histiocytoma and chondrosarcoma
- The most common primary BEGNIN chest wall tumors are chondroma, desmoids and fibrous dysplasia

Tumors of the Sternum, Scapula and Clavicle

1. Primary tumors of the manubrium and the sternum constitute 15 % of the chest wall tumors, but nearly all are malignant
2. The sternum is a frequent site metastasis from the breast, thyroid and kidney
3. The scapula is not a frequent site of metastasis (except mesothelioma)
4. Primary tumors of the clavicle are uncommon, but 90 % are malignant
5. The clavicle is more a site of a metastasis than a primary tumor

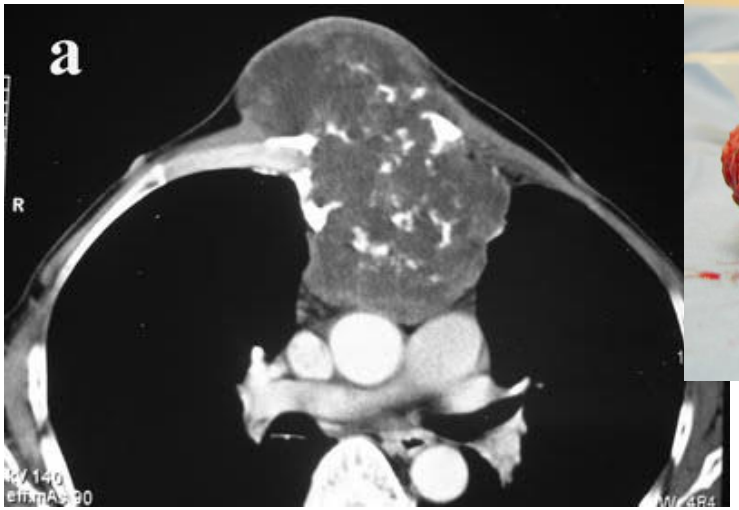

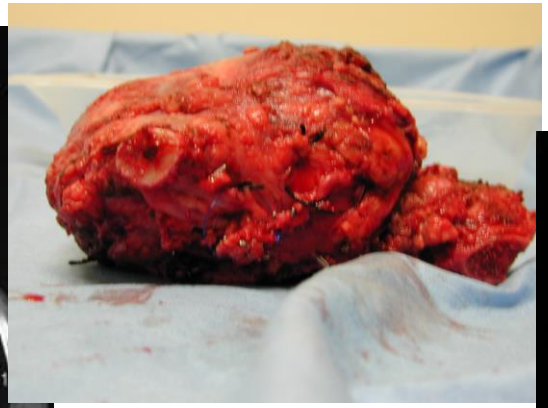

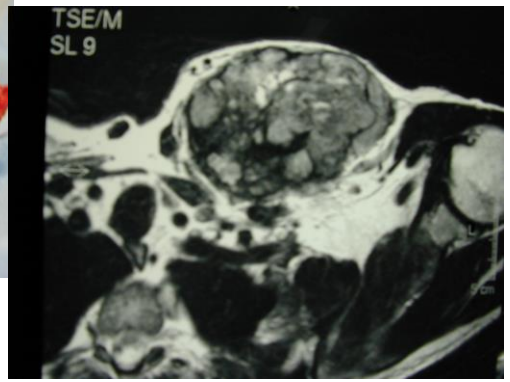

Treatment (1)

- Wide resection is essential
- Margins of 4 cm are desirable
- For tumors of rib cage, involved ribs, partial ribs above and below the tumor must be removed

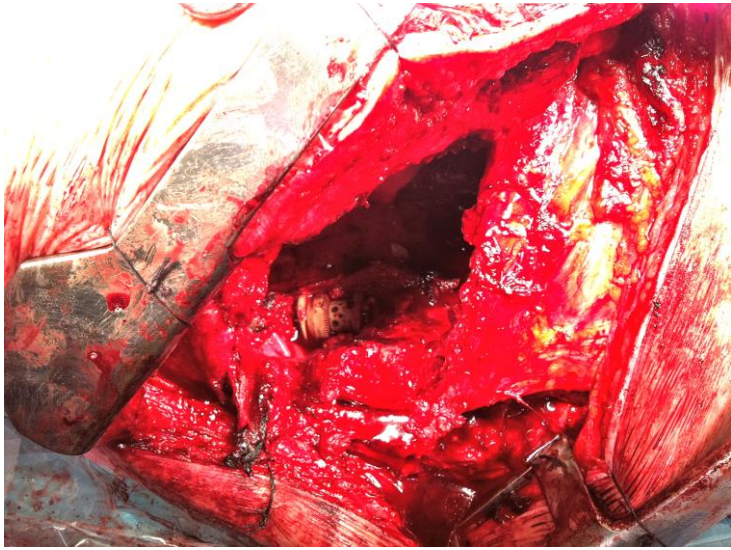

Treatment (2)

For tumors of the sternum, resection of the involved bone and corresponding costal arches is indicated

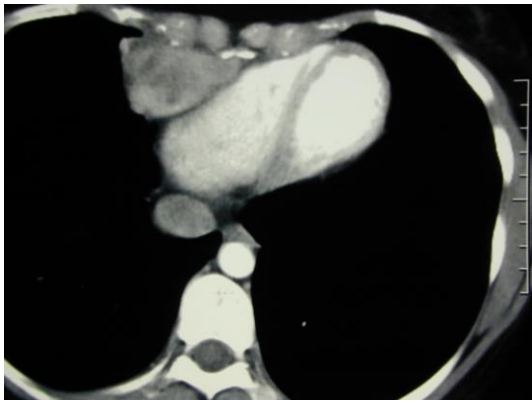

Any involved structure, such as lung, thymus, chest wall muscle or pericardium must be removed

The role of resection of chest wall metastasis and recurrent breast cancer is controversial

Chest wall reconstruction : what are we aiming for?

1) **Chest wall stability**
2) Prevent hernia formation
3) Prevent reduction of operated hemithorax leading to scoliosis
3) Scapular support
4) Protection of thoracic structures
5) Cosmesis

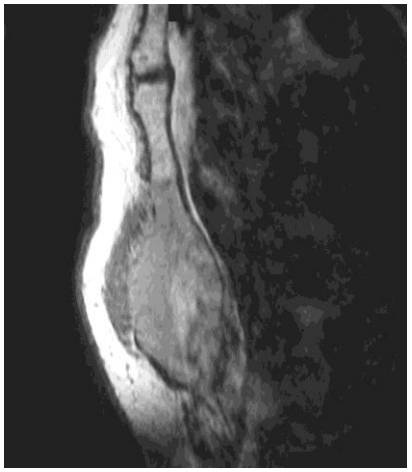

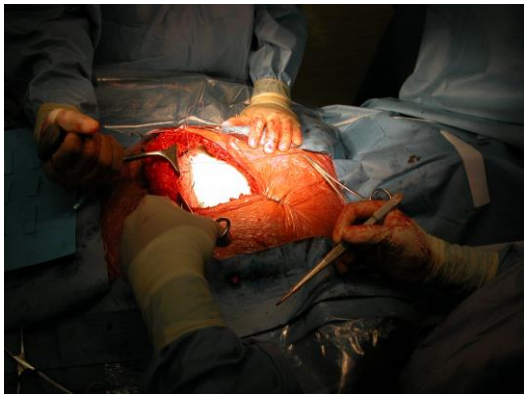

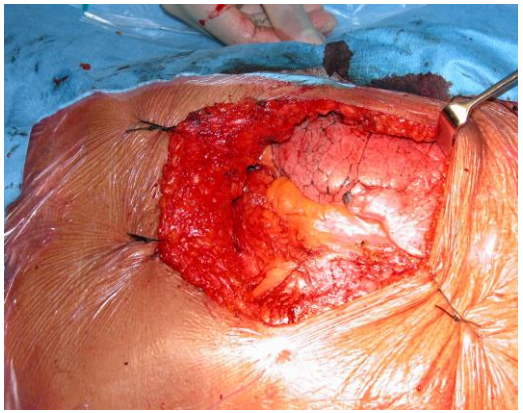

When do we reconstruct?

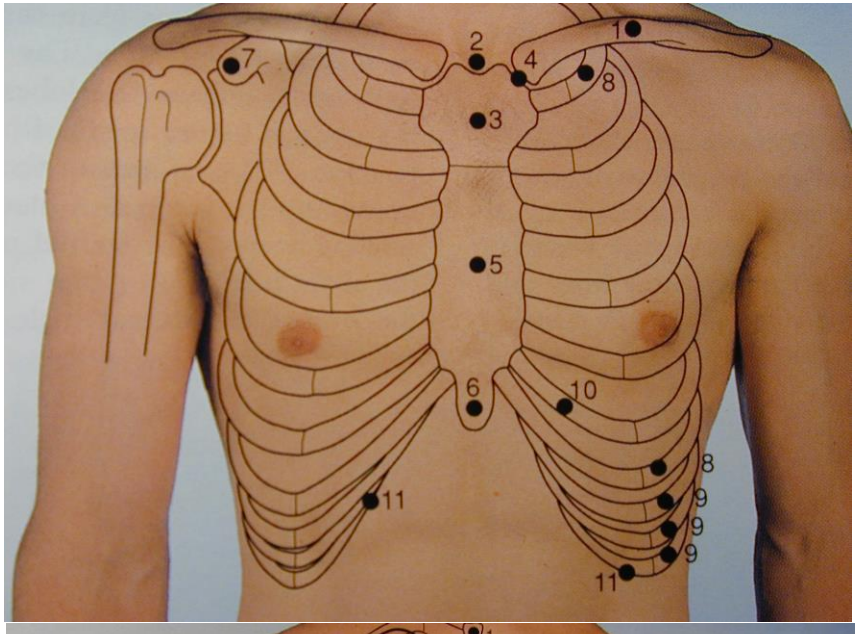

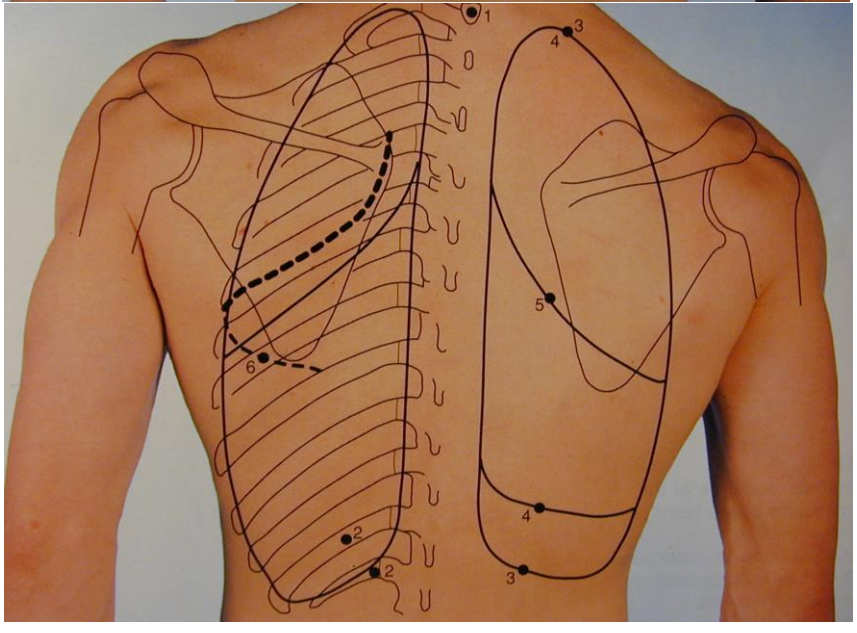

- Anterior defects
- Lateral defects
- Costochondral defects
- Mainly lower

Usually more than 2-3 ribs as long as:

1. Length of rib
2. Connection of rib

Remember !

Scapula covers posterior parietal defects, but :

- > 5th rib no need for cover
- < 5th rib : cover to prevent impaction of scapula
- > 5 ribs : cover to prevent flail chest

Principles of chest wall reconstruction

Restore morphology and function !

- Volume
- Tightness
- Rigidity
- Cover with viable tissue
  - muscle flap
  - omentum
- Skin closure
  - primary ideal
  - musculo-cutaneous flap
  - skin grafting

How to restore tightness ?

Tightness of chest wall

- Different materials available
  - absorbable mesh
  - non absorbable mesh
  - PTFE
- Caveats :
  - none does restore volume & rigidity
  - all require cover with muscle or omentum
  - prefer absorbable if infection
  - *no cover required if defect is beneath the scapula*

Prosthetic materials in thoracic surgery

Synthetic

- Silicon
- PTFE
- MARLEX MESH
- POLYPROPELENE

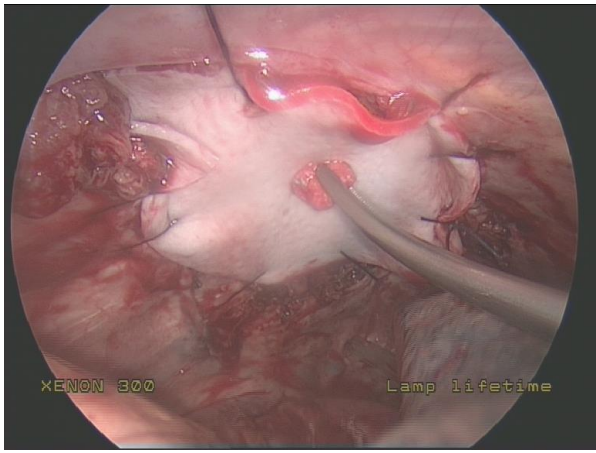

Biological

- A cellular matrix
- Cryopreserved human fascia lata
- Autologous flaps

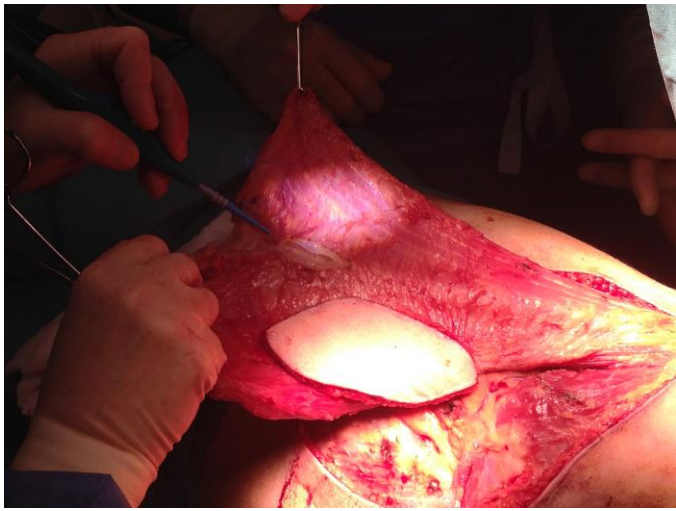

Marlex

Pros:

✓ well incorporated into the tissue

Cons:

- does not achieve a watertight seal

- if contaminated, complete removal is laborious

PTFE

Pros:

- ✓ **easy to stretch and mold**
- ✓ **provides a watertight closure**
- ✓ **if contaminated,**
  conservative treatment possible,
  complete removal easy
- ✓ **well seen on CT scan**

Cons:

- **seroma is frequent**
- **not rigid enough in flail chest area**

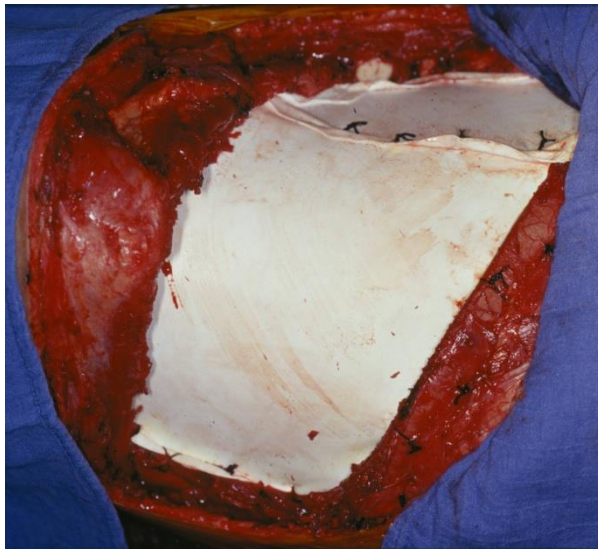

Soft Reconstruction materials SYNTHETIC

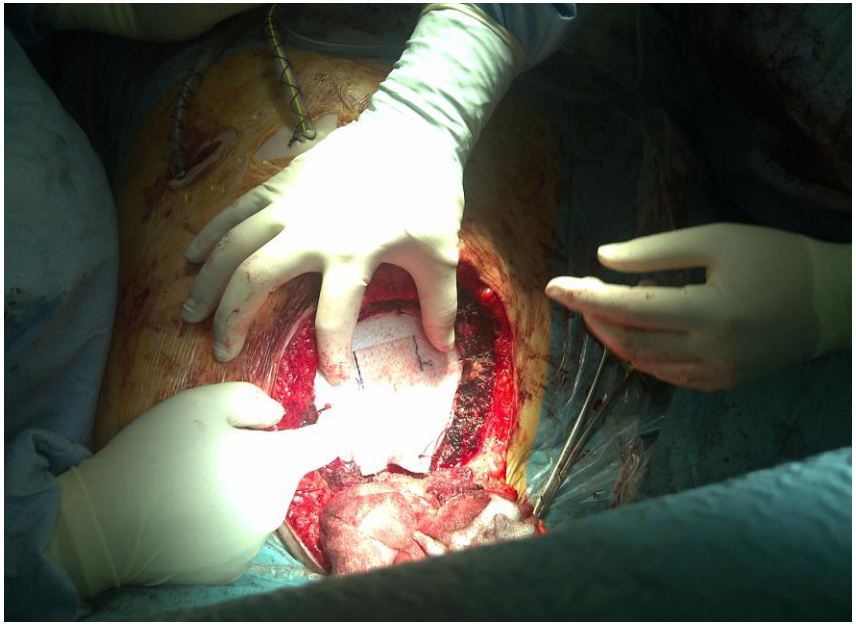

- Relatively inexpensive
- Readily available
- In different sizes
- *No need for rigid add on i.e. bars*
- Infection risk
- Difficult to remove
- Can be a problem in redo surgery
- Not suitable for infected cases

Soft Reconstruction materials
Biological

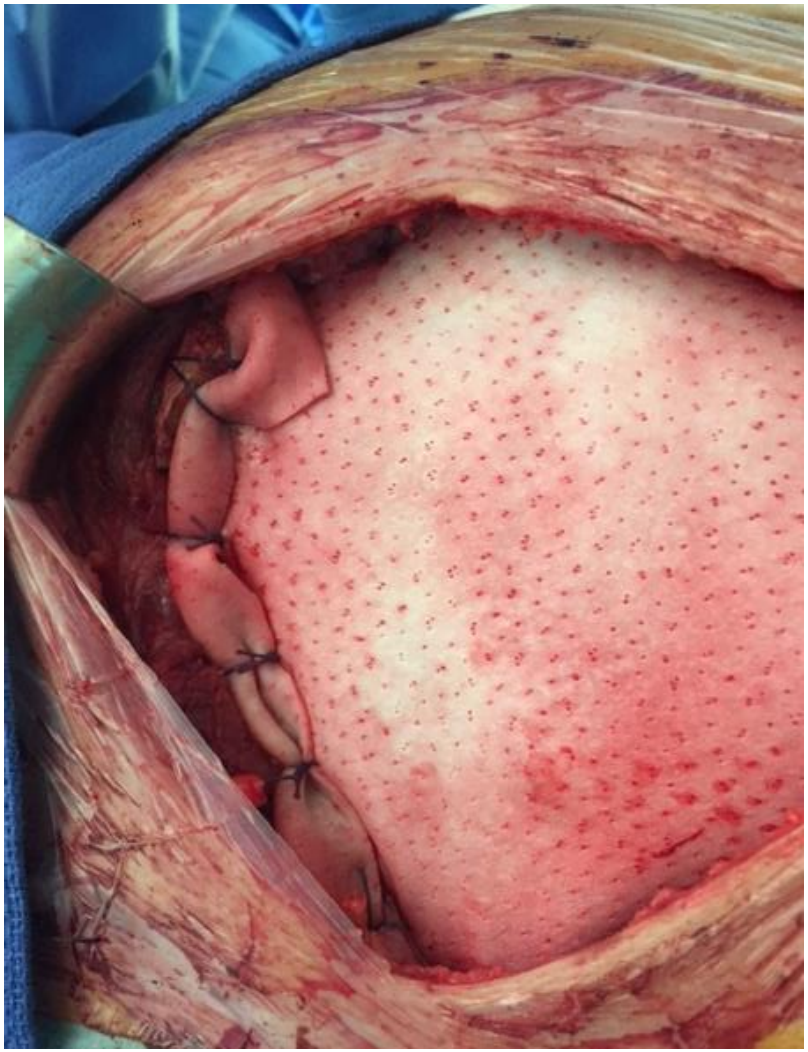

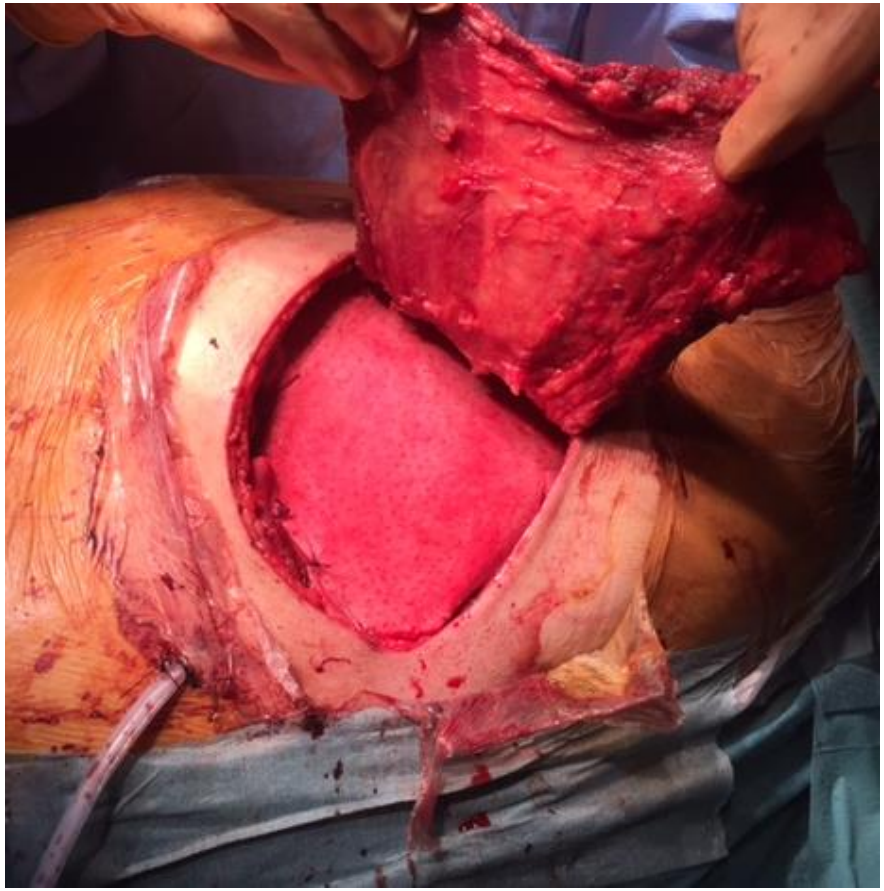

The ideal **biological** mesh

Primary characteristics

- **Rigid enough**
- **Malleable enough**
- **Radiolucent**

The ideal **biological** mesh

Secondary characteristics

- **Cheap and cheerful**
- **Incorporate well to the body**
- **Durable**
- **Physically and chemically inert**
- **Resistant to infection**
- **Resistant to strain**
- **No ‘foreign body’ reaction**
- **Non-carcinogenic**
- **Hypoallergenic**
- **Sterilizable**

XCM Biologic Tissue Matrix

- A sterile non-crosslinked 3-D matrix derived from porcine dermis
- Kensey Nash's proprietary Optrix™ process
- Native matrix structure for excellent strength
- Allows cellular migration & infiltration
- Removes cells and DNA for host acceptance
- Minimizes damage to the tissue architecture

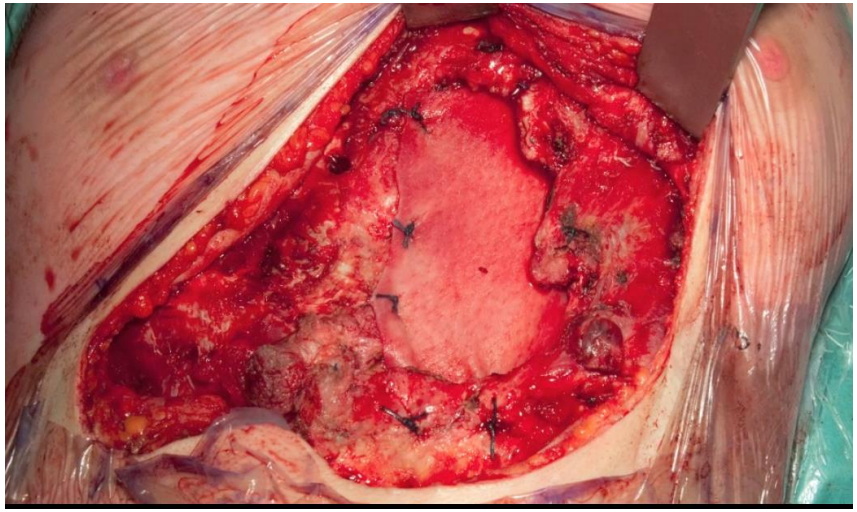

Permacol™
Permanent Surgical Implant

Key Features & Benefits

- Hydrated, ready-to-use; packed in sterile saline
- Eliminates the chance of contamination during soaking
- No preparation time
- Stored at room temperature
- No pre stretching required
- Multiple sizes to minimize waste and reduce cost

Approved and proved Indications

- Reinforcement and repair of soft tissue
- Defects of the thoracic wall
- Muscle flap reinforcement
- Plastic and reconstructive surgical applications

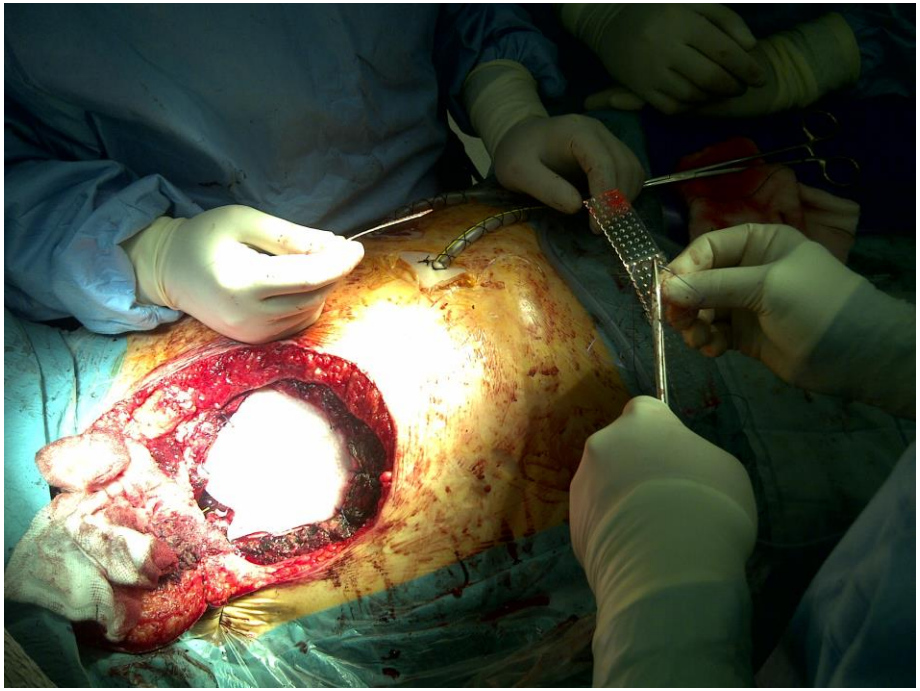

How to restore Rigidity ?

How to restore rigidity & volume

- Methyl-metacrylate
  - unphysiologic
  - toxic for tissues
- Rib subtitutes
  - STRATOS
    - Easy & intuitive use
    - Titanium = tissue friendly
    - Close to normal anatomy
  - MATRIX

Methylmethacrylate-cement

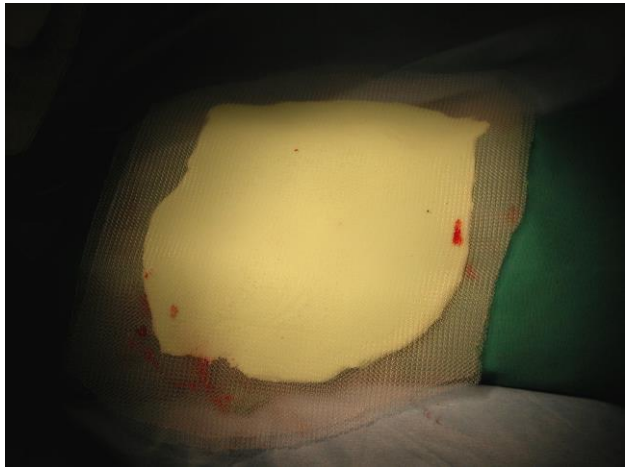

1. Inexpensive
2. Easy to use in all defects
3. Good integrity
4. Difficult to remove
5. Can cause reaction
6. Not suitable in infected cases
7. Rigidity may cause pain

Chest wall reconstructive surgery with *STRATOS implants*



- Defect bridging after tumor removal or related reconstructive surgery of chest wall structures + GORE-TEX

Titanium rib clips and bars : « Stratos™ »

Pros:

- **quick and easy to use**
- **greater stability**
- **biocompatibility**
- **resistance to infection**
- **allows MRI imaging**

Cons:

- **it does cost more than the standard treatment, but it's the only solution to get as close as possible to an anatomical reconstruction !!!**

Titanium bars fixation system

1. can bridge gaps
2. Inert material
3. Can be shaped to need
4. No need to be removed
5. Questionable use in infected cases

CRYOPRESERVED ribs or sternum

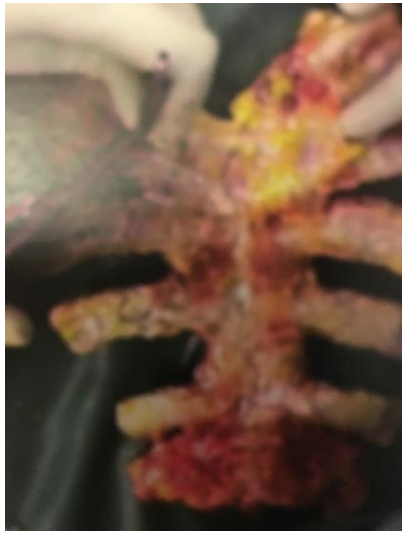

1. Expensive
2. Not available to all
3. Inert material
4. No risk of infection
5. Can conform to shape of defect
6. Incorporates to recipient tissues

How to restore Soft tissue coverage ?

Muscle flaps

Mathes and Nahai classification

- I ONE PEDICLE
- II DOMINANT AND MINOR PEDICLE
- III 2 DOMINANT
- IV SEGMENTAL PEDICLES
- V ONE DOMINANT AND SECONDARY PEDICLES

Common muscle flaps

Muscle	Blood supply	Main characteristics
Latissimus dorsi	Thoracodorsal vessels (standard flap)	The most frequently used flap in thoracic surgery due to its large volume, long arc of rotation and clear anatomy It reaches almost any part of the chest[42]
	Perforators from the last intercostal and lumbar vessels (reversed flap)	More difficult to prepare due to the variable anatomy of the vessels and with a limited arc of rotation Useful for defects located in the inferior part of the chest[43,44]
Serratus anterior	Branch from the thoracodorsal vessels plus lateral thoracic vessels	Large volume (comparable with that of the latissimus dorsi muscle) The arc of rotation is smaller than that of the latissimus dorsi muscle but it easily reaches the hilar region Very useful in reoperations after posterolateral thoracotomy since the most part of this muscle remains intact; it can be used after previous anterolateral thoracotomy, unless the feeding branch was ligated[37,40,41]
Pectoralis major	Pectoral branch (dominant to the sternocostal head) and clavicular branch (dominant to the clavicular head) of the thoraco-acromial trunk	Used mainly for defects in the apical region, although it may reach the pulmonary hilum
	Perforators from intercostal and internal thoracic vessels	Used for defects located in the paramedial area[26,45,46]
Intercostal	Intercostal vessels (anterior and posterior)	Frequently used for reinforcement of the bronchial stump or bronchial fistula closure During thoracomyoplasty, pleuro-periosto-intercostal flaps corresponding to the resected ribs may have a significant volume, being useful for filling dead angles and cul-de-sacs[15,23]
Rectus abdominis	Superior epigastric artery	Used for defects in the lower part of the chest, although the tip of this flap may reach the sternal notch[47]

Rectus abdominis

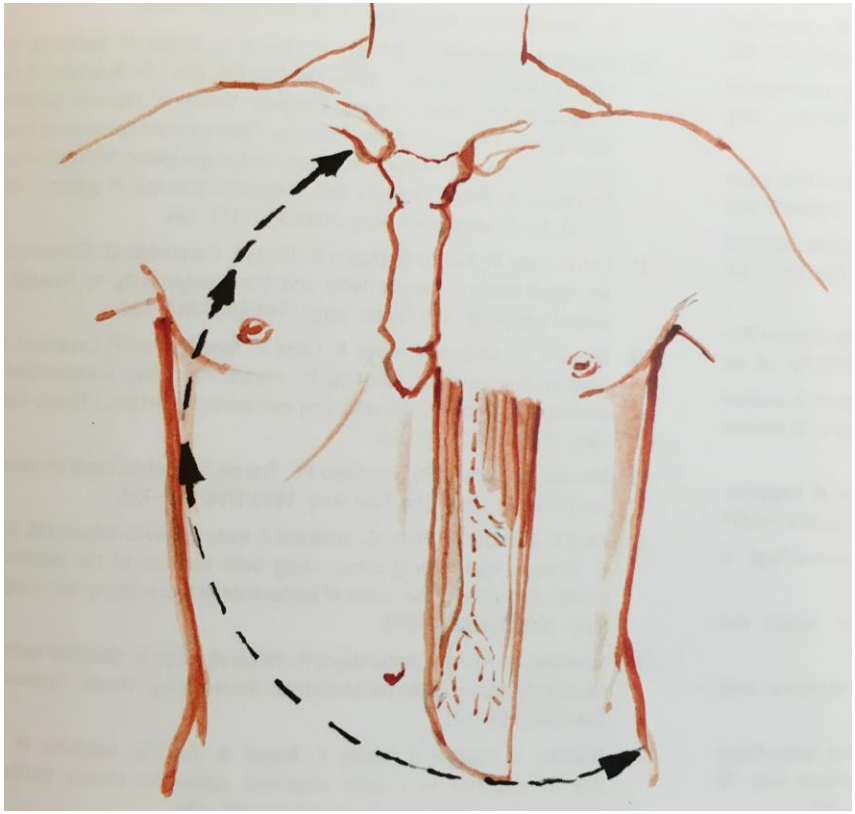

Latissimus dorsi

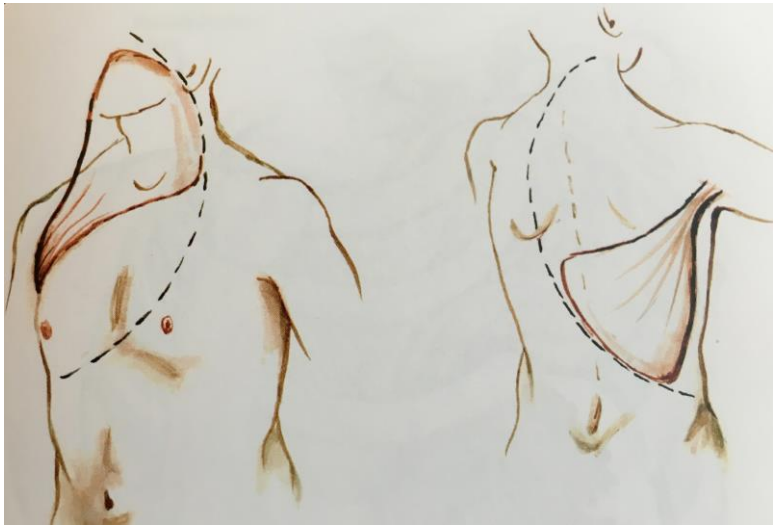

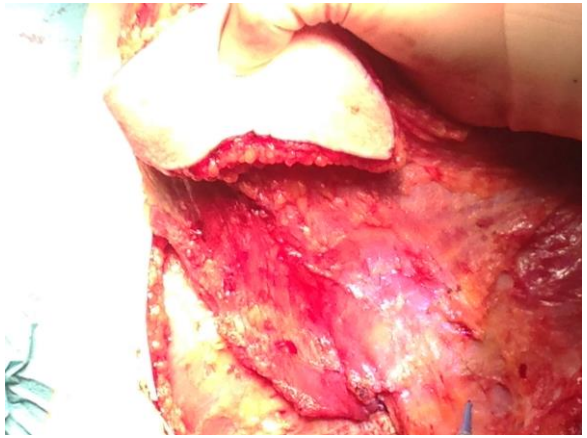

Free flap technique

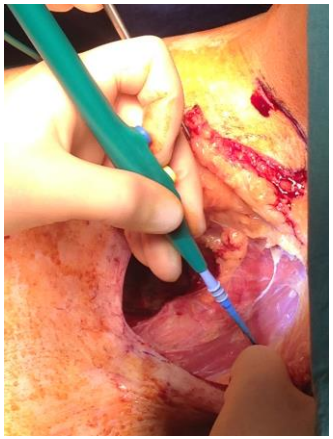

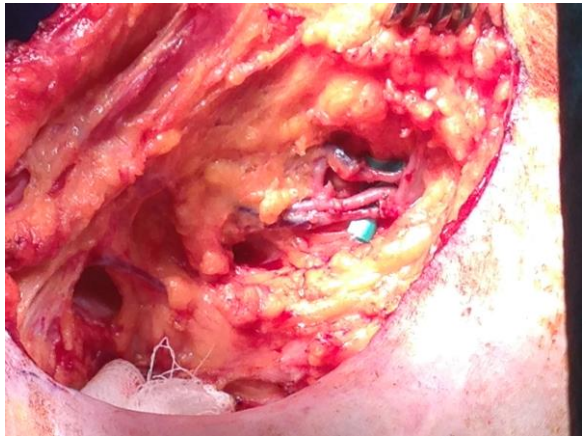

Free flap technique

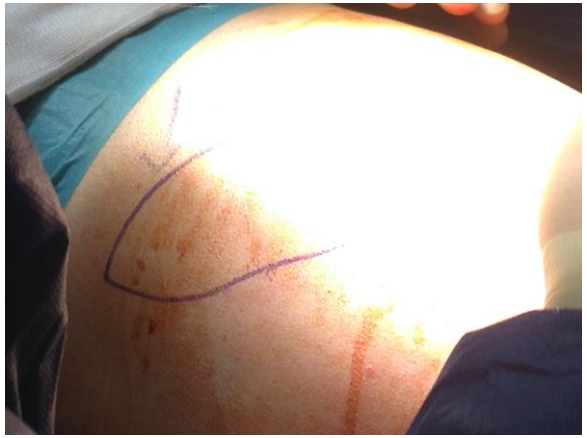

Free flap technique

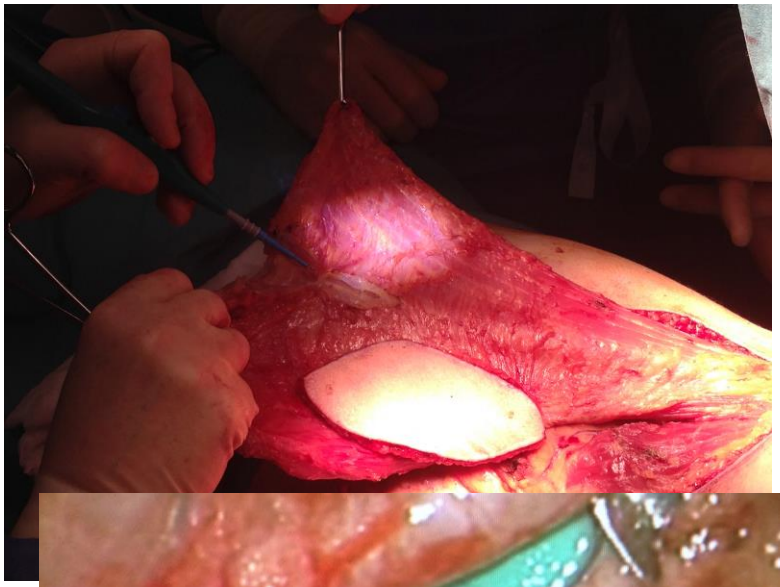

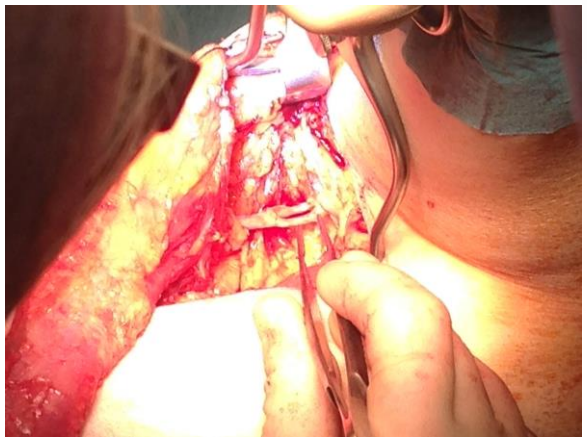

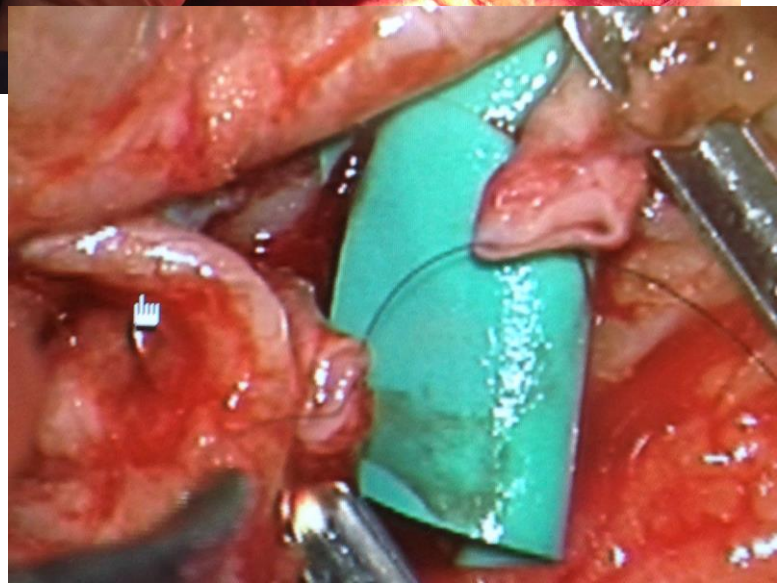

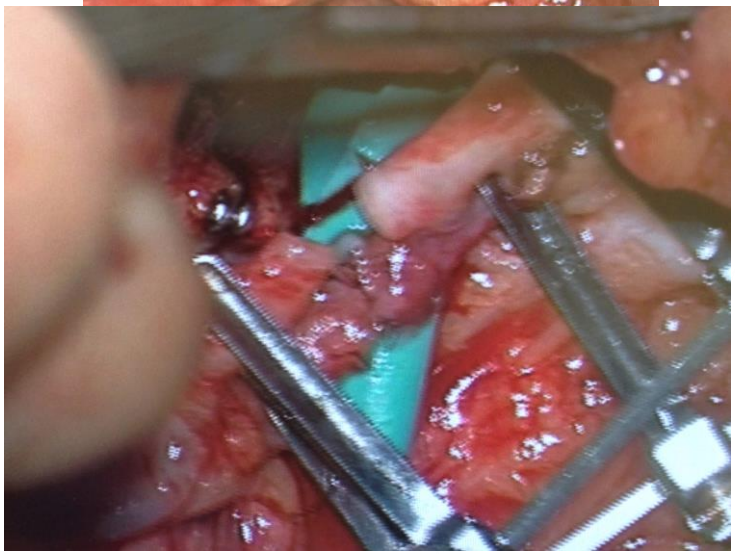

Combination with skin graft

Consider that:

- Muscle shrinks when detached
- Complete haemostasis is achieved
- Flap is viable and well vascularised

(usually wait 20-30 min in theatre before waking up patient)

How to cover a chest wall prothesis

	muscle	omentum
Sternal area	Pectoralis - rectus	Yes
Breast area	Pectoralis - latissimus	Yes
Anterolateral	Latissimus - rectus	Yes
Posterolateral	Latissimus	No
Apico-posterior	No cover	No cover

Chest wall tumor
removal – reconstruction – complication
From A to Z…

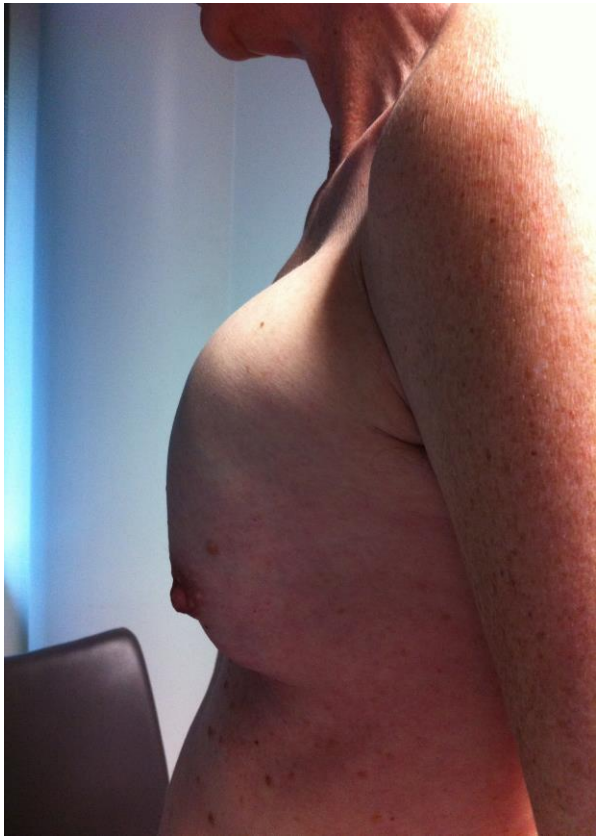

Right anterior chest wall chondrosarcoma

Latissimus dorsi muscle flap

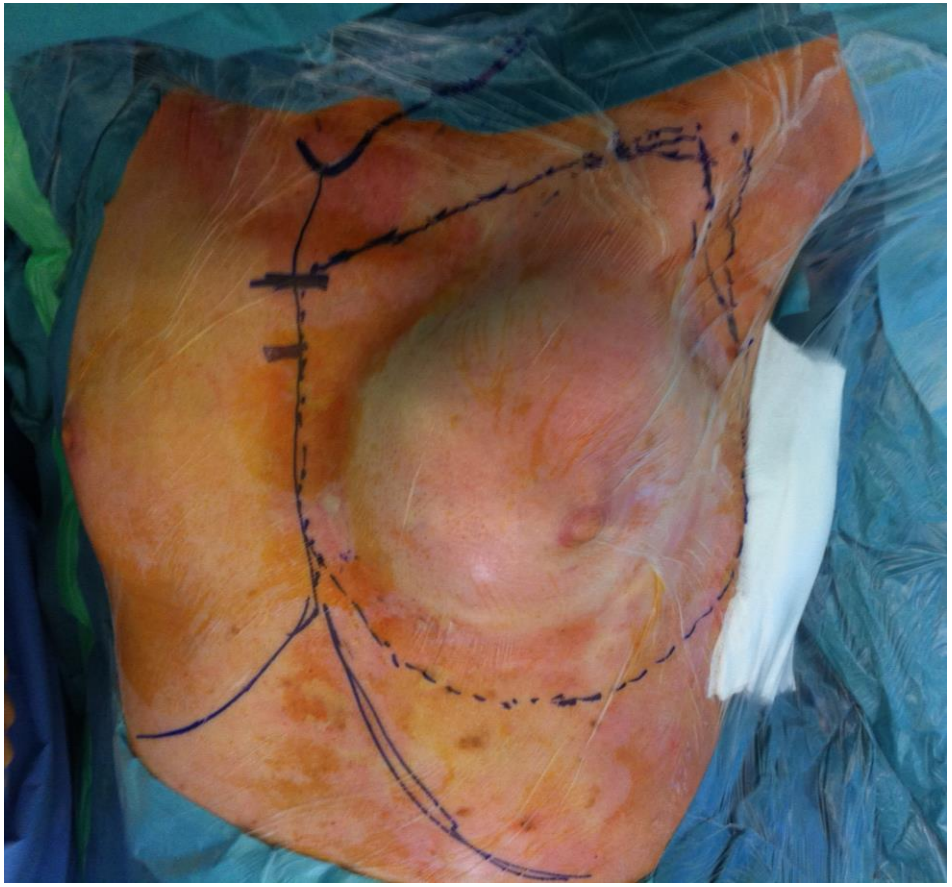

Skin incision (safety margin)

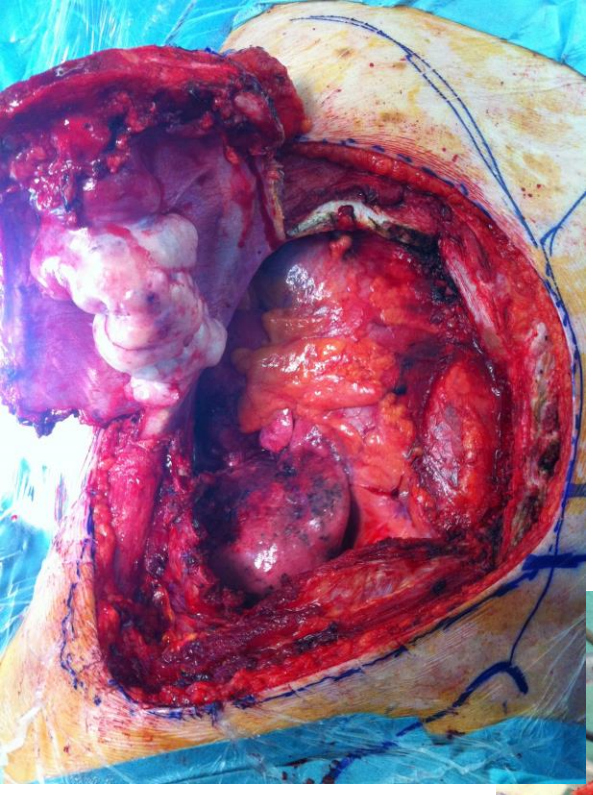

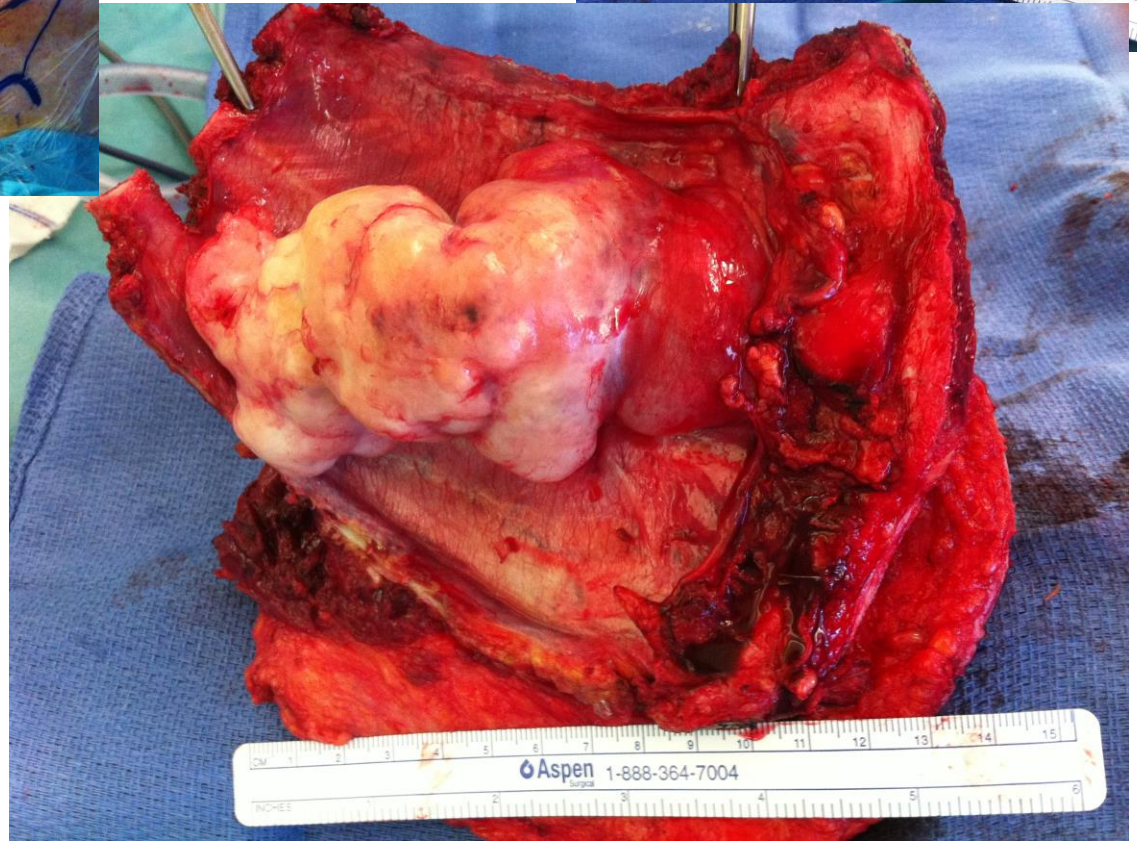

Postoperative specimen

Guess what now????

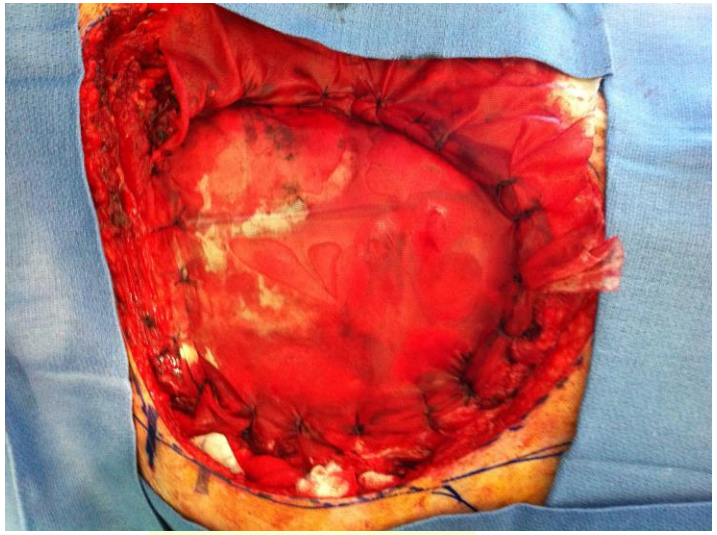

Vicryl 1st layer

Titanium Bars

Vicryl 2nd layer

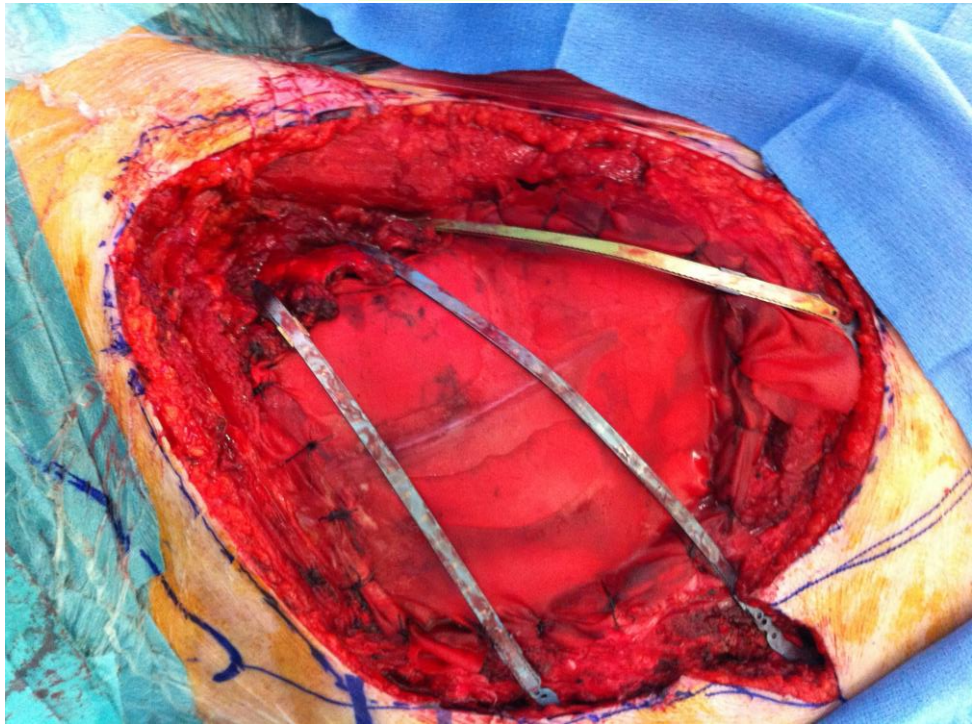

Thigh skin graft

Soft tissue coverage with latissimus dorsi muscle flap

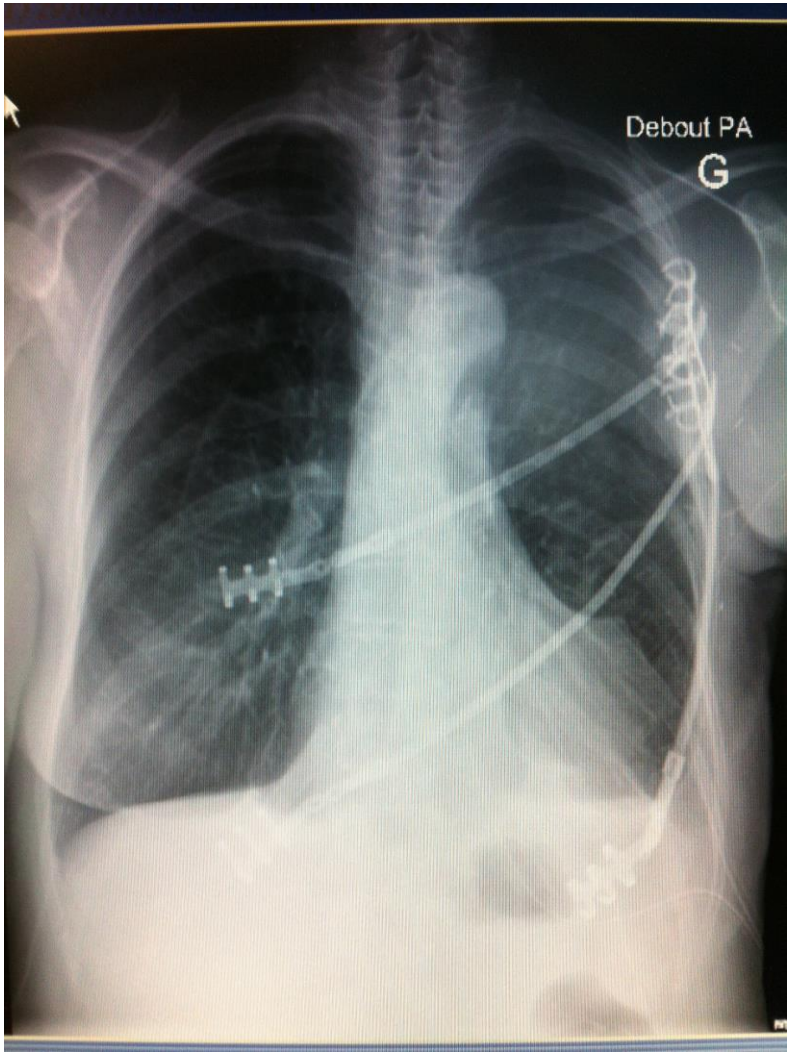

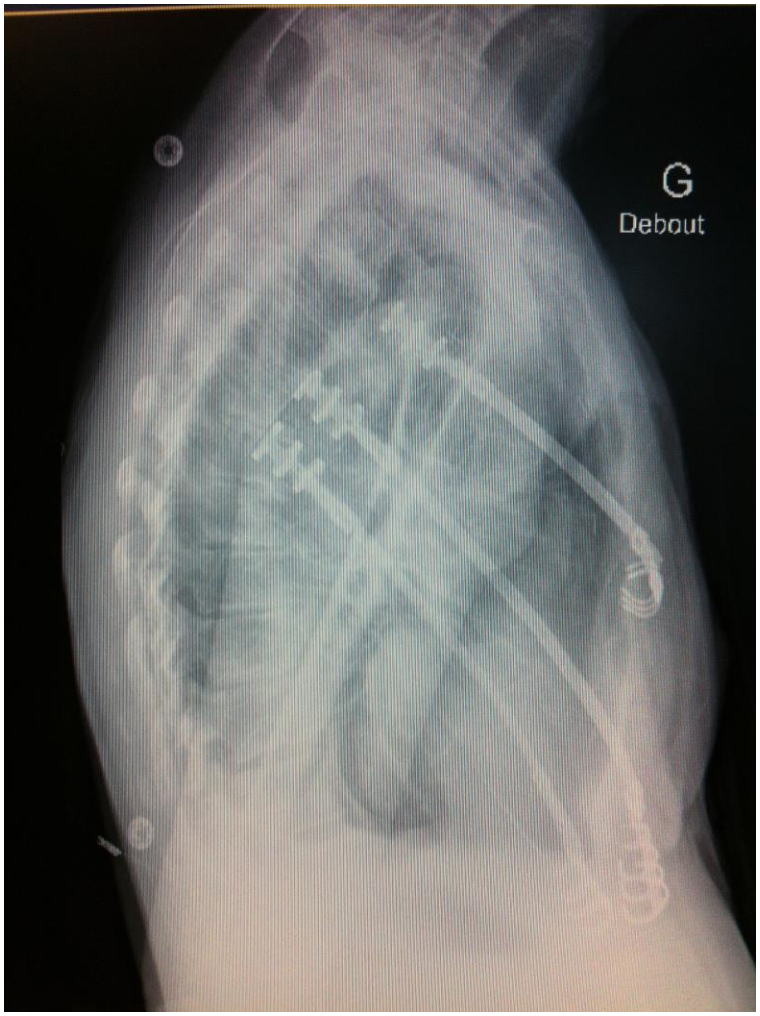

Postoperative chest X-ray

One month follow-up

Six month follow-up
After RT

Guess what now????

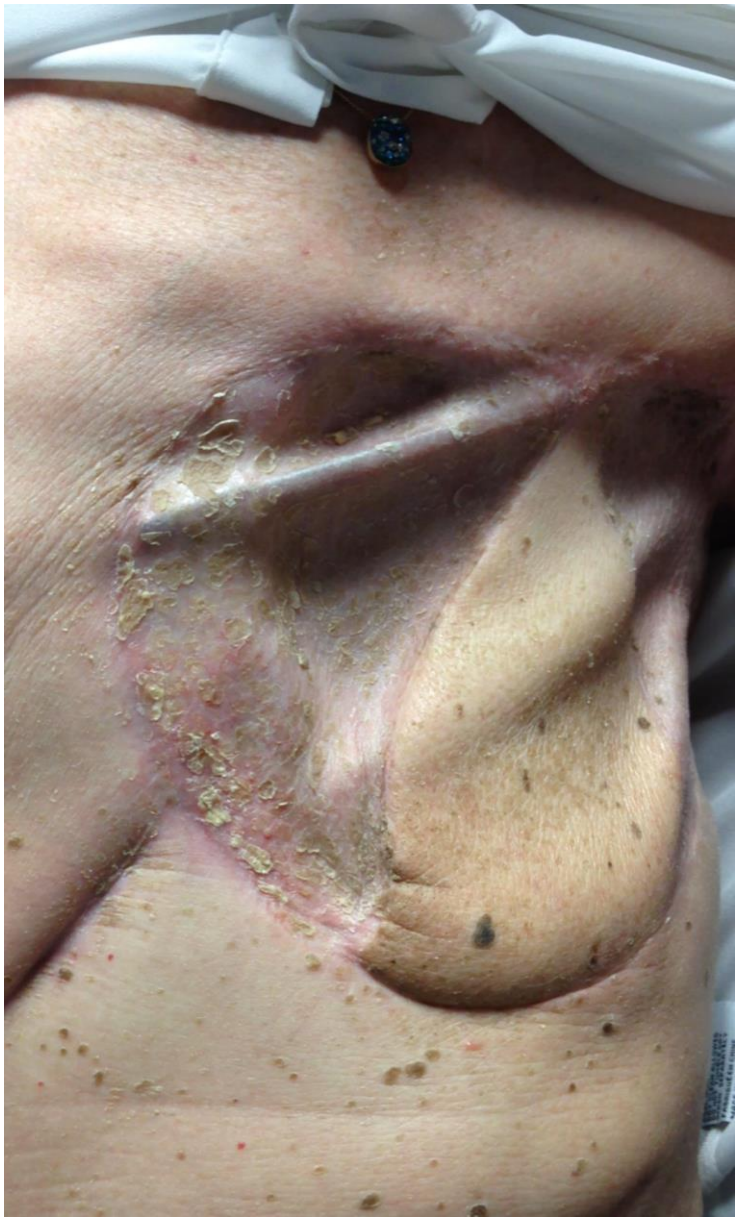

One year later…

Skin necrosis and disunity ± bar infection

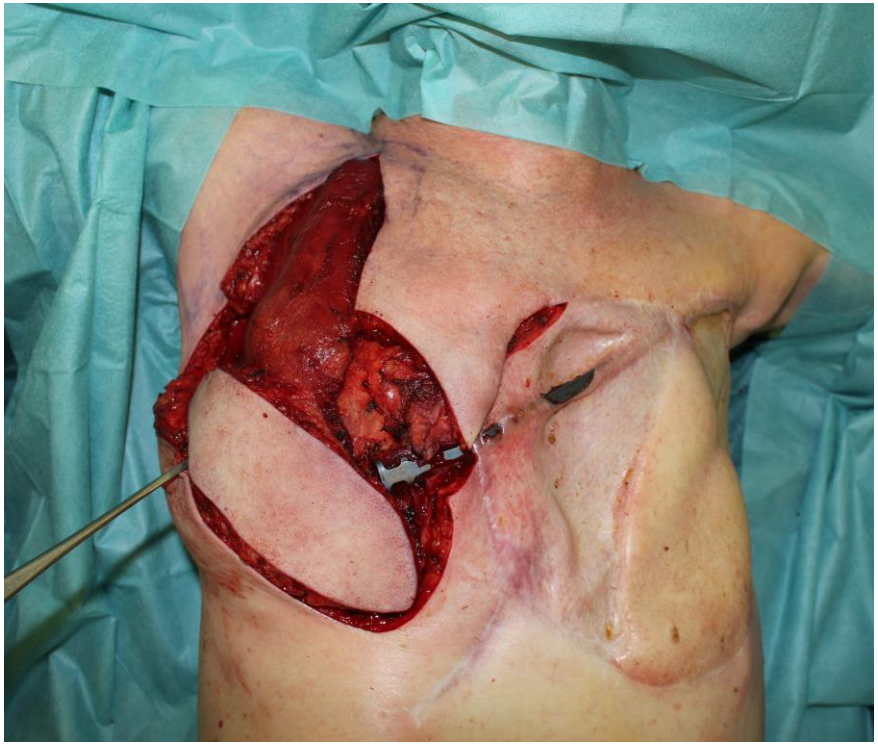

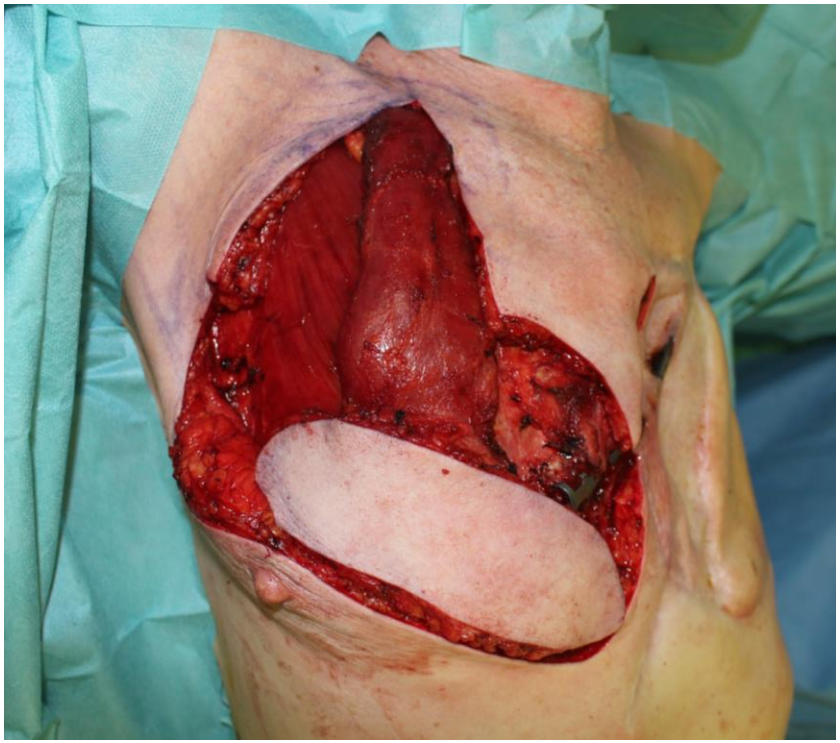

Pectoralis major muscle flap

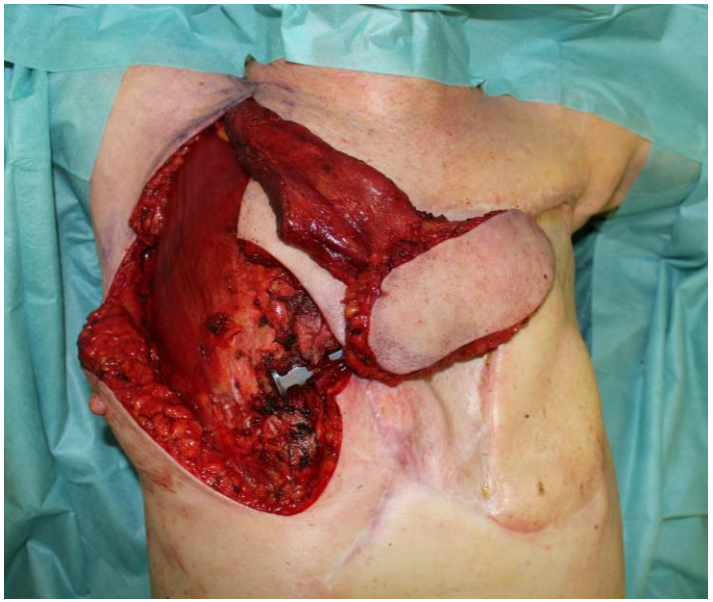

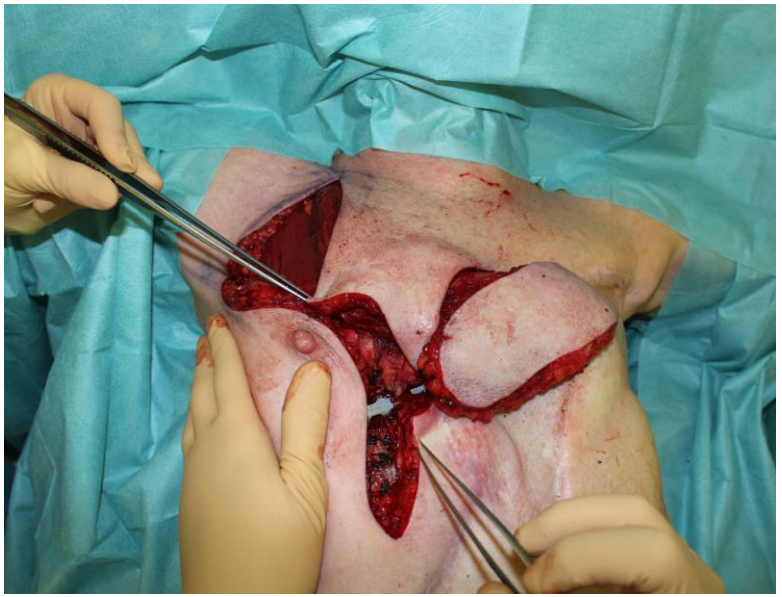

Muscle flap coverage (bars are let in place after cleaning)

.....

Guess what now????

2nd bar fracture
Repair
with New clip at the forefront
….

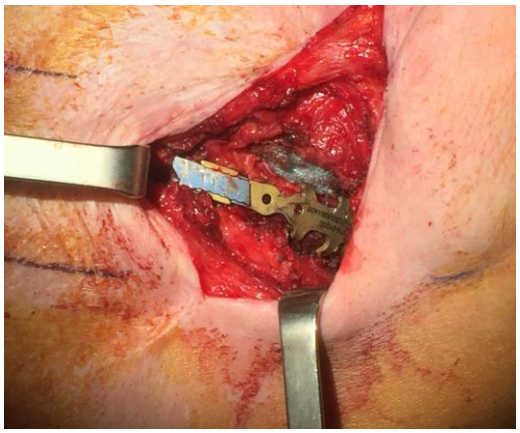

Take - home messages

- Choice of material

  1. location of defect

  2. size of defect

  3. presence or absence of infection

  4. surgeon's choice

- Good long term results:

  1. when indications followed

  2. meticulous technique

  3. use of familiar material